

TIMESAVINGS FOR CONTOUR GENERATION IN HEAD AND NECK IMRT: MULTI-INSTITUTIONAL EXPERIENCE WITH AN ATLAS-BASED SEGMENTATION METHOD

K. Hu¹, A. Lin², A. Young¹, G. Kubicek², J.W. Piper^{3,4}, A.S. Nelson³, J. Dolan¹, R. Masino¹, M. Machtay²

¹Beth Israel Medical Center, New York, NY, Department of Radiation Oncology • ²Thomas Jefferson University, Philadelphia, PA
³MIMvista Corp., Cleveland, OH • ⁴Department of Computer Science, Wake Forest University, Winston-Salem, NC

Purpose

The widespread use of IMRT for head and neck cancer requires comprehensive and consistent target delineation. Manual contouring is a major workflow obstacle for which a more rapid but accurate solution is needed. The purpose of this study is to evaluate the timesavings for initial contour generation by implementing an atlas-based segmentation (ABS) method into the clinical workflow for two different institutions.

Materials and Methods

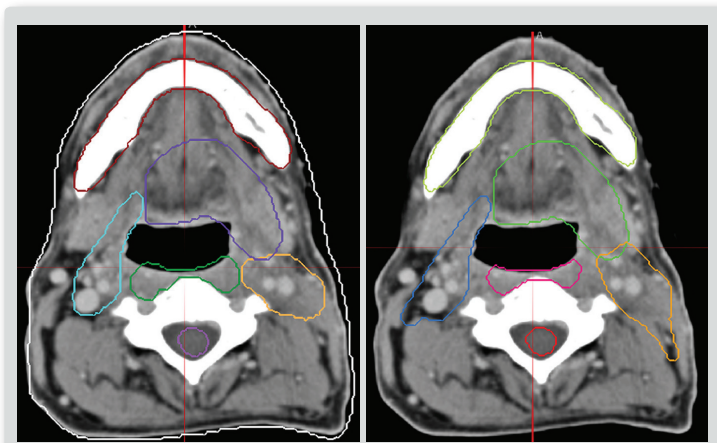
Commercially available software was used for atlas creation and automatic ABS (MIMvista Corp, Cleveland, OH). Each institution created customized atlases containing a library of previously treated patients to reflect its institutional guidelines for normal tissue and PTV delineation. Institution #1 (I1) created an atlas of oropharynx (OPX) and nasopharynx (NPX) patients with 13 subjects each. Institution #2 (I2) created an atlas of OPX and larynx (LAX) patients with 15 subjects each. Three patients for each site were randomly selected for comparison of ABS to manual contouring. For each patient, the best fit atlas subject was automatically selected and contours were automatically deformed onto the patient's CT scan in under 5 minutes. The I1 attending edited the atlas contours directly and the I2 attending edited the contours after the resident edited the atlas contours. The time to manually contour the patient and subsequently edit by an attending was recorded.

Results

At I1, the difference in time required for the attending physician to edit the resident's contours and the atlas contours was not statistically significant. The resident's contours required 2.7% and 31% less time to edit for OPX and NPX, respectively, than the ABS contours (p=0.33). Total physician contouring timesavings using ABS was 83% for normal structures, 91% for nodal targets, 90% for primary targets (PT), and 87% overall.

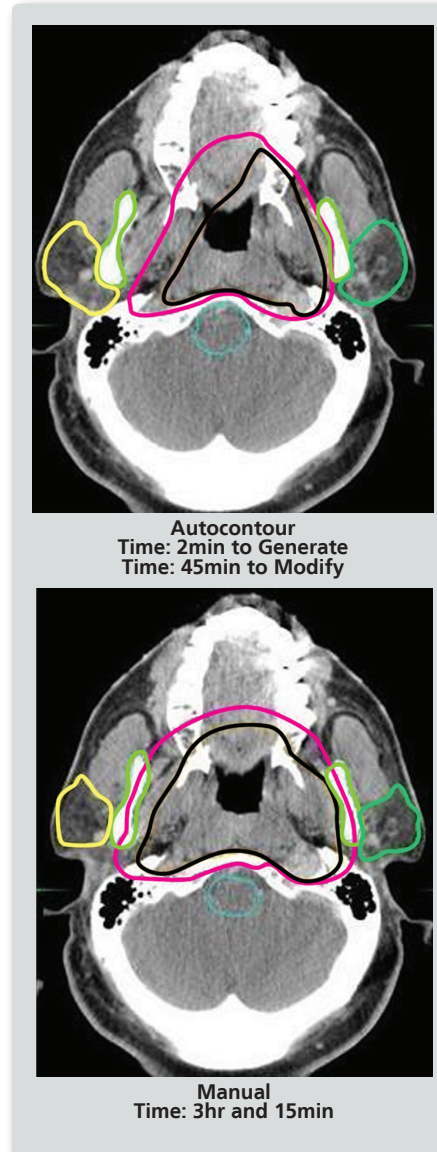
Because four patients randomly selected for evaluation were uncharacteristically "easy" T1 patients, the contouring required at I2 was not as complex as at I1. At I2, ABS followed with editing by a resident and attending physician saved 62% and 50% compared with manual contouring for OPX and LAX patients, respectively. Considering only normal structures and nodal targets increases the timesavings to 79% for OPX, 56% for LAX, and 68% for all patients.

Figure 1
Patient with Base of Tongue Cancer



Patient with base of tongue cancer contoured with atlas before (left) and after (right) staff physician editing.

Figure 2
Atlas-based Autocontouring



Patient with nasopharynx cancer.

Conclusions

ABS was shown at I1 to be nearly as helpful to the attending physician as resident contours and resulted in an overall contouring timesavings of 87%. I2 experienced 68% reduction in contouring time for nodal targets and normal structures and 25% for primary targets. Greater timesavings was experienced for complex patients and additional timesavings is expected as the atlases increase in size.